

## Mirizzi syndrome type V: laparoscopic management

Gonzalo Andrés Domínguez Alvarado <sup>a,1</sup>; Daniela D'Vera Camargo <sup>b,1</sup>; Iván David Lozada Martínez <sup>c,2</sup>; Felipe López Ramírez <sup>d,3</sup>; Luis Ernesto López Gómez <sup>e,1</sup>

<sup>a</sup> MD. Specialist in clinical epidemiology. Professor, Director of the Surgical Research and Innovation Group. Founder and Coordinator of Semillero de

Innovación e Investigación en Cirugía (SIIC – UNAB). ORCID: <https://orcid.org/0000-0002-7512-8733>, [gdominguez@unab.edu.co](mailto:gdominguez@unab.edu.co); <sup>b</sup> Medical intern. ORCID: <https://orcid.org/0000-0002-4901-7490>, [dd@unab.edu.co](mailto:dd@unab.edu.co); <sup>c</sup> Medical student. ORCID: <https://orcid.org/0000-0002-1960-7334>, [ivandavidloma@gmail.com](mailto:ivandavidloma@gmail.com); <sup>d</sup> Biomedical engineer. MD. Researcher at The Institute for Cancer Care at Mercy Medical Center. ORCID: <https://orcid.org/0000-0002-1560-9172>, [jf.lopez718@uniandes.edu.co](mailto:jf.lopez718@uniandes.edu.co); <sup>e</sup> MD. Specialist in General and Oncological Surgery. Fellowship in obesity, São Paulo's Gastro Obeso Center. ORCID: <https://orcid.org/0000-0002-3666-2159>, [cirurgia@unab.edu.co](mailto:cirurgia@unab.edu.co)

1. Universidad Autónoma de Bucaramanga 2. Universidad de Cartagena. 3. Universidad de los Andes.

DOI: <https://doi.org/10.22517/25395203.24657>

### Abstract

**Introduction:** Mirizzi's syndrome is an infrequent complication of biliary lithiasic disease, with an incidence of less than 1% in developed countries, being even less frequent the type V variant. Current literature disagrees on the management of this condition, stating that laparoscopic surgery is not safe as a standard procedure.

**Clinical Case:** We present the case of Mirizzi's Syndrome in an 80-year-old man, which is referred to the emergency department for suspicion of sepsis of abdominal origin, with ultrasound study of cholelithiasis, pneumobilia and dilation of the bile ducts. Retrograde endoscopic cholangiopancreatography was performed with technical impossibility for the mobilization and extraction of large-size stones, resorting to exploration through laparoscopic technique, obtaining satisfactory results.

**Conclusion:** It is necessary to emphasize that the type of Mirizzi syndrome, the patient's characteristics and the surgeon's experience directly influence the treatment modality, its complications and/or success rates. In the present case, the experience of the main author in the management of minimally invasive procedures and the consideration of reducing the risk of complications such as infections in a fragile patient, were the factors that influenced the decision for laparoscopic intervention.

**Key words:** Mirizzi Syndrome, Cholelithiasis, Cholangitis, Laparoscopy.

### Síndrome de Mirizzi tipo V: Manejo laparoscópico

#### Resumen

**Introducción:** El Síndrome de Mirizzi es una complicación infrecuente de la enfermedad litiasica biliar, con una incidencia menor al 1% en países desarrollados, puede desarrollarse en cinco variantes, siendo menos frecuente la variante tipo V. La literatura actual discrepa sobre el manejo de esta condición, afirmando que la cirugía laparoscópica no es segura como procedimiento estándar.

**Caso Clínico:** Se presenta el caso de Síndrome de Mirizzi en un hombre de 80 años, que es remitido al departamento de urgencias por sospecha de sepsis de origen abdominal, con estudio ecográfico de colelitiasis, neumobilia y dilatación de las vías biliares. Se realizó Colangiopancreatografía retrógrada endoscópica con imposibilidad técnica para la movilización y extracción de los cálculos por gran tamaño, recurriéndose a exploración a través de técnica laparoscópica, obteniéndose resultados satisfactorios.

**Conclusión:** Para tratar el Síndrome de Mirizzi, es necesario considerar las características del paciente y la experiencia del cirujano ya que ambos factores influyen directamente en la modalidad del tratamiento, sus complicaciones y tasas de éxito. En el presente caso, la experiencia del autor principal en el manejo de procedimientos mínimamente invasivos y la consideración de reducir el riesgo de complicaciones como infecciones en un paciente frágil, fueron los factores que influyeron para la decisión de intervención laparoscópica.

**Palabras clave:** Síndrome de Mirizzi, Colelitiasis, Colangitis, Laparoscopia

## Introduction

Mirizzi Syndrome (MS), also known as extrinsic biliary compression syndrome, was first described in 1948 by the Argentinian surgeon Pablo Luis Mirizzi as a rare complication of biliary stone disease (1). This syndrome is characterized by extrinsic compression of the bile duct, produced by pressure applied indirectly by one or more stones embedded in the infundibulum of the gallbladder (Hartmann's bag) or cystic duct, resulting in partial or complete obstruction of the duct, which can end in liver dysfunction (1), (3). In turn, the resulting chronic inflammation and ulceration can trigger internal fistulas from the gallbladder to the common hepatic duct, common bile duct, and duodenum (2),(4).

It is an infrequent presentation pathology, with an incidence of less than 1% per year in developed western countries, and 4.7% -5.7% in developing countries (3). In Colombia, prevalence of around 4% have been reported (5). This entity does not have pathognomonic signs, however, it has been found that obstructive jaundice is the most common presentation (50-100%), and that it is frequently accompanied by pain in the right upper quadrant or epigastric pain, and may also present with fever, nausea, vomiting, coluria, chills, tachycardia and anorexia (1), (2), (6), (7).

Over time, several classifications have been described for this syndrome, currently the most used is the one modified by Csendes et al (8) in 2007, and validated by Beltrán et al (9) who establish of five types (**Table 1**).

**Table 1:** Classification of Mirizzi Syndrome

Mirizzi Classification	Definition	Clinical manifestations	Diagnosis	Treatment
<b>Type I</b>	External compression of the bile duct by an impacted stone in the infundibulum of the gallbladder or cystic duct	Jaundice, abdominal pain, nausea, vomiting, dark urine	Abdominal ultrasonography, CT, magnetic cholangioresonance, ERCP, intraoperative diagnosis.	Fundoquistic cholecystectomy with cholangiography without bile duct exploration and removal of gallstones
<b>Type II</b>	Biliary-enteric fistula affecting less than one third of the bile duct circumference	Jaundice, abdominal pain, nausea, vomiting, dark urine	Abdominal ultrasonography, CT, magnetic cholangioresonance, ERCP, intraoperative diagnosis.	(I) Subtotal cholecystectomy; (II) Stone removal, bile duct suture and T-tube placement; (III) Roux-en-Y Hepato-jejunostomy; (IV) Cholecysto-cholecystectomy-duodenostomy; (V) Cholecysto-cholecystectomy-jejunostomy.
<b>Type III</b>	Bilio-enteric fistula covering up to two thirds of the circumference of the duct	Jaundice, abdominal pain, nausea, vomiting, dark urine.	Abdominal ultrasonography, CT scan, magnetic resonance cholangiography, ERCP, intraoperative diagnosis.	(I) Subtotal cholecystectomy; (II) Stone removal, bile duct suture and T-tube placement; (III) Roux-en-Y Hepatojejunostomy; (IV) Cholecysto-cholecystectomy-duodenostomy
<b>Type IV</b>	Biliary-enteric fistula with complete bile duct obstruction.	Jaundice, abdominal pain, nausea, vomiting, dark urine.	Abdominal ultrasonography, CT, magnetic resonance cholangiography, ERCP, intraoperative diagnosis.	(I) Subtotal cholecystectomy; (II) Duodenal bilioenteric anastomosis; (III) Roux-en-Y hepato-jejunostomy
<b>Type V</b>	Includes the presence of a biliary-enteric fistula along with any other Mirizzi			
<b>Type Va</b>	Includes a bilio-enteric fistula without biliary ileus.	Jaundice, abdominal pain, nausea, vomiting, dark urine.	Abdominal ultrasonography, CT scan, magnetic resonance cholangiography, ERCP, intraoperative diagnosis.	(I) Division and simple suture of bilioenteric fistulas in the involved viscera; (II) Total or subtotal cholecystectomy depending on the presence of a cholecystobiliary fistula.
<b>Type Vb</b>	Includes a bilio-enteric fistula with biliary ileus.			(I) Treatment of biliary ileus; (II) In second intention total or subtotal cholecystectomy.

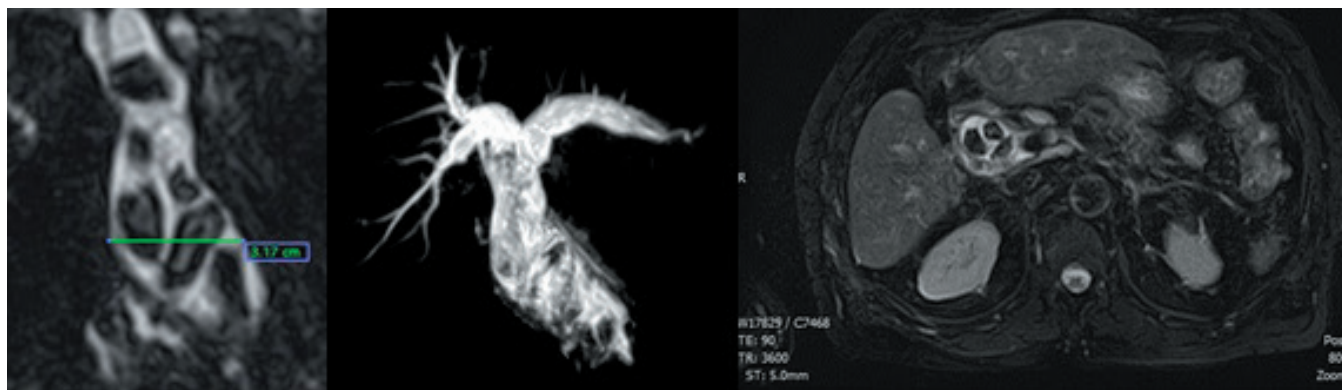
The preoperative diagnosis of MS is given by the clinic, laboratory tests and diagnostic images such as abdominal ultrasonography, computerized axial tomography (CT), Magnetic Resonance Cholangio (MRI) and Endoscopic Retrograde Cholangio-Pancreatography (ERCP) (2). Given the low incidence and therefore little experience, preoperative diagnosis is not easy, with ranges between 8 and 63.4% of cases.

The current literature disagrees on the management of this condition, stating that laparoscopic surgery is not safe as a standard procedure, much less, in patients with advanced disease (10-12). However, in recent years, this technique has positioned itself as a treatment option due to its excellent results. The objective of this manuscript is to share the experience in the management of Mirizzi Syndrome type V by laparoscopy, without complications and with a satisfactory recovery.

## Presentation of the case

An 80-year-old male patient with a history of Type 2 Diabetes Mellitus and Arterial Hypertension in goals, who was admitted to the emergency department for suspicion of sepsis of abdominal origin, with an ultrasound study of cholelithiasis, pneumobilia and dilatation of the bile ducts. On physical examination, he was in a fair general condition, hemodynamically stable, jaundiced, coluric, with mild pain on palpation in the right upper quadrant, without signs of peritoneal irritation, and without neurological deficit.

Admission paraclinics are performed, where moderate leukocytosis and neutrophilia are found. Hyperbilirubinemia at the expense of direct bilirubin and moderate normochromic normocytic anemia. Based on the findings, a probable diagnosis of grade III cholangitis and grade II cholecystitis is established, with manifestations suggestive of choledocholithiasis, which is why CRMN is indicated (**Figure 1**), observing severe dilation of the extrahepatic bile duct and pneumobilia, consistent with choledocholithiasis. Massive gallbladder is not identified. Based on the findings, a definitive diagnosis of choledocholithiasis is established.



**Figure 1:** Intra and extrahepatic bile duct dilation. The common hepatic duct and the common bile duct are distended, at the intrapancreatic level the common bile duct reaches a caliber of 27 mm, inside the two canals, multiple faceted nodular images can be seen, with variable diameters ranging between 3 and 15 mm. The gallbladder was not identified. There are signal changes in the ductal system in the left lobe that suggest pneumobilia.

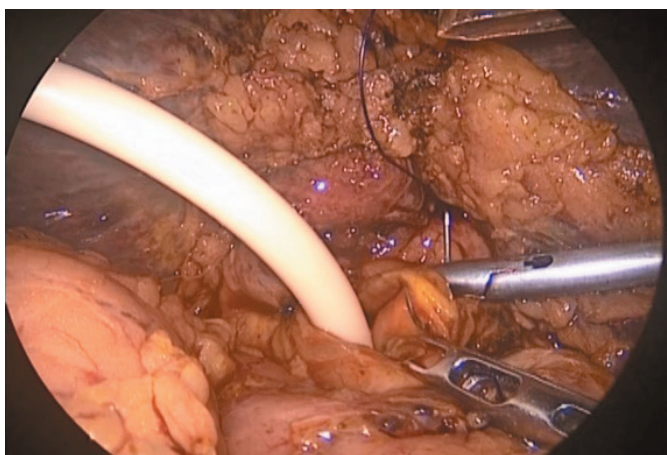
ERCP is indicated, being carried out normally but with technical impossibility for the mobilization and extraction of the stones due to their large size. Due to the deterioration of the clinical picture, it was decided to undergo conventional surgical exploration of the bile duct, opting for the laparoscopic technique.

During the intervention, a chronic inflammatory plastron is identified that involves the greater omentum, hepatic flexure of the colon, and the duodenum. The first major finding was the confirmation of “absence of gallbladder”, finding in its place a small fibrous and atrophic remnant, adhered to the main bile duct. The second important finding was the great dilation of the common bile duct with a diameter of 3 cm and firmly attached to the second portion of the duodenum. At this level, the presence of a common bile duodenal fistula was identified.

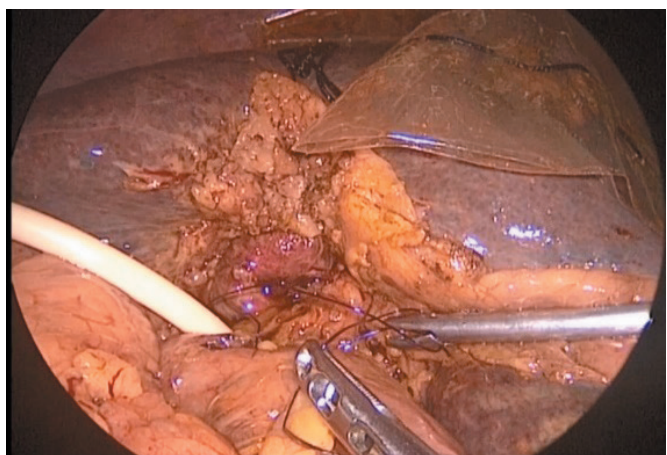Once the dissection and separation of these epithelia had been carried out, laparoscopic suturing of the duodenum was carried out. Subsequently, we proceeded to perform a wide longitudinal choledochotomy with discharge of biliary-purulent material. Multiple faceted stones were identified and removed, the largest measuring 2 cm in diameter. Laparoscopic exploration of the common bile duct, changing the lens for a 5 mm diameter 30 ° lens,

allowed proximal and distal observation until all the stones were extracted. In this maneuver, a biliary stent with previous endoscopic transduodenal placement was identified, leaving it in place. After exhaustive lavage and exploration with a balloon catheter (Fogarty), a biliary drainage tube (Kher’s T-tube) was placed (**Figure 2**), and the choledochotomy was closed with a 3/0 caliber polydioxanone intracorporeal laparoscopic suture (**Figure 3**). The operative time was two and a half hours, with minimal bleeding.

**Figure 2:** Intraoperative photograph. Placement of biliary drainage tube (Kher T-Tube).



**Figure 3:** Intraoperative photograph. Closure of choledochotomy with 3/0 caliber polidoxanone intracorporeal laparoscopic suture.



During the postoperative period, the patient presented adynamic ileus that emerged spontaneously. Upon observing satisfactory evolution, he was discharged from hospital after five days. Two weeks later, the biliary drainage tube was removed, and in the four-week follow-up, complete resolution of the condition was evidenced without complications.

## Discussion

The low incidence of MS globally and the presentation of nonspecific biliary symptoms constitute a challenge for early diagnosis and effective treatment. Today, the initial study for suspected biliary disease is abdominal ultrasonography. Through this non-invasive and inexpensive means, gallstones and cholecystitis can be identified. In very few cases, the finding of an atrophic gallbladder and an ectasis common hepatic duct with an integral common bile duct suggests the presence of MS.

However, this test has only 29% diagnostic accuracy and a sensitivity of 8.3% -27% (13).

On the other hand, the MCRN is a study of high sensitivity and specificity in the detection of stones and stenosis of the bile duct, since it allows to show the narrowing of the common bile duct, the presence of a lithium in the cystic duct and the dilation of the duct intra and extra hepatic, in addition to the illustration of the biliary tree, an important characteristic that will serve as a guide in the performance of endoscopic or surgical procedures (14), (15). Currently, the gold standard for the diagnosis of MS are the images provided by ERCP. Technique that allows wide visualization of the extrahepatic bile ducts, in addition to clearly showing extrinsic compression by impacted gallstones, being able to accurately determine the presence and location of fistulas (2). It has a sensitivity of 76.2% and some studies even report a sensitivity of 100% (4), (16). Likewise, on multiple occasions it is used as an initial or complementary treatment to the surgical procedure. However, the diagnosis of MS is identified and confirmed in most cases during the intraoperative period.

The definitive solution for MS consists of surgical treatment (2). Pathological changes generate distortion of the anatomy due to dense adhesions as a consequence of chronic inflammation. This increases the risk of internal biliary fistula, and therefore, an increased risk of injury to the bile duct or massive hemorrhage during the dissection of the triangle of Calot (16). Traditionally, open surgery has been considered the technique of choice for the treatment of MS (4). This as a result of its relative safety compared to the laparoscopic technique, which is associated with high conversion rates (31% - 100%), and a higher incidence of bile duct injuries (16).

Currently, this management is controversial, since the minimally invasive laparoscopic approach has multiple advantages. Shorter hospital stays, better use of resources, lower postoperative infection rates, among others (2). Some authors mention that laparoscopy is only safe if performed in patients with type I MS, however, Yuan et al (17) carried out a prospective study, where they demonstrated that laparoscopic subtotal cholecystectomy was successful in all patients with Type II MS without conversions or morbidity, together with a shorter hospital stay ( $7.21 \pm 1.61$  vs  $15.31 \pm 3.82$  days,  $P < 0.01$ ), less blood loss ( $162.81 \pm 40.83$  vs  $207.55 \pm 37.01$  mL,  $P = 0.425$ ), and without significant difference in the recurrence rate (4.55% vs 9.52%,  $P = 0.522$ ) of choledocholithiasis (17). However, there is little literature that talks about the effectiveness and safety of laparoscopy in MS type III, IV and V (17-20).

It is necessary to highlight that the type of MS, the characteristics of the patient and the experience of the surgeon directly influence the treatment modality, its complications and / or success rates. In the present case, the experience of the main author in the management of minimally invasive procedures and the consideration of reducing the risk of complications such as infections in a frail patient were the factors that influenced the decision for laparoscopic intervention. In order to define the safety and efficacy of this laparoscopy vs open surgery in the management of MS, it is necessary to carry out multicenter studies with the highest level of evidence, which allow the detailed evaluation of various variables that may influence peri and postoperative results.

## References

1. Valderrama-Treviño AI, Granados-Romero JJ, Espejel-Deloiza M, Chernitzky-Camaño J, Barrera Mera B, Estrada-Mata AG, et al. Updates in Mirizzi syndrome. *HepatoBiliary Surg Nutr.* 2017; 6(3):170–8.
2. Jones MW, Ferguson T. Mirizzi Syndrome. 2021 Feb 8. In: StatPearls [Internet]. Treasure Island (FL): StatPearls Publishing; 2021 Jan–. PMID: 29494098.
3. Beltrán MA. Mirizzi syndrome: History, current knowledge and proposal of a simplified classification. *World J Gastroenterol.* 2012; 18(34):4639–50.
4. Chen H, Siwo EA, Khu M, Tian Y. Current trends in the management of Mirizzi Syndrome: A review of literature. *Medicine (Baltimore).* 2018 Jan;97(4):e9691. doi: 10.1097/MD.00000000000009691.
5. Rodríguez Carolina AG. El síndrome de compresión biliar extrínseca benigna o síndrome de Mirizzi: experiencia de cinco años en el Hospital de San José. *Rev Colomb Cirugía.* 2008; 23:6-11.
6. Lee KF. Mirizzi syndrome: a new approach to an old problem. *Hepatobiliary Surg Nutr.* 2018; 7(1):56-57.
7. Kimura J, Takata N, Lefor AK, Kanzaki M, Mizokami K. Laparoscopic subtotal cholecystectomy for Mirizzi syndrome: A report of a case. *Int J Surg Case Rep.* 2019; 55:32-34.
8. Csendes A, Muñoz C, Albán M. Síndrome de Mirizzi - Fístula colecistobiliar, una nueva clasificación. *Rev Chil Cir.* 2007; 59(Suppl):63–64.
9. Beltran MA, Csendes A, Cruces KS. The relationship of Mirizzi syndrome and cholecystoenteric fistula: Validation of a modified classification. *World J Surg.* 2008; 32(10):2237–43.
10. Al-Akeely MHA, Alam MK, Bismar HA, Khalid K, Al-Teimi I, Al-Dossary NF. Mirizzi syndrome: Ten years experience from a teaching hospital in Riyadh. *World J Surg.* 2005; 29(12):1687–92.
11. Borz-Baba C, Levy DA, Cohen ME. Post-Cholecystectomy Mirizzi Syndrome: A Case Report and Review of the Literature. *Am J Case Rep.* 2019; 20:1290-1298.
12. Erben Y, Benavente-Chenhalls LA, Donohue JM, Que FG, Kendrick ML, Reid-Lombardo KM, et al. Diagnosis and treatment of Mirizzi syndrome: 23-year mayo clinic experience. *J Am Coll Surg.* 2011; 213(1):114–9.
13. Bo LI, Xun LI, Wen-ce Z, Ming-yan HE, Wen-bo M, Lei Z, et al. Effect of endoscopic retrograde cholangiopancreatography combined. 2013; 126(18):3515–8.
14. Reverdito R, De Moricz A, De Campos T, Pacheco Júnior AM, Silva RA. Síndrome de Mirizzi graus III e IV: Tratamento cirúrgico. *Rev Col Bras Cir.* 2016; 43(4):243–7.
15. Yetişir F, Şarer AE, Acar HZ, Parlak O, Basaran B, Yazıcıoğlu O. Laparoscopic Resection of Cholecystocolic Fistula and Subtotal Cholecystectomy by Tri-Staple in a Type V Mirizzi Syndrome. *Case Reports Hepatol.* 2016; 2016:1–4.
16. Alemi F, Seiser N, Ayloo S. Gallstone Disease: Cholecystitis, Mirizzi Syndrome, Bouveret Syndrome, Gallstone Ileus. *Surg Clin North Am.* 2019; 99(2):231-244.
17. Yuan H, Yuan T, Sun X, Zheng M. A Minimally Invasive Strategy for Mirizzi Syndrome Type II: Combined Endoscopic with Laparoscopic Approach. *Surg Laparosc Endosc Percutaneous Tech.* 2016; 26(3):248–52.
18. Xu XQ, Hong T, Li BL, Liu W, He XD, Zheng CJ. Mirizzi syndrome: Our experience with 27 cases in PUMC Hospital. *Chinese Med Sci J.* 2013; 28(3):172–7.
19. Clemente G, Tringali A, De Rose A, Panettieri E, Murazio M, Nuzzo G, et al. Mirizzi Syndrome: Diagnosis and Management of a Challenging Biliary Disease. *Can J Gastroenterol Hepatol.* 2018; 2018:6962090.
20. Seara Costa R, Vieira F, Costa JM, Ferreira A. Mirizzi syndrome: when the gallbladder meets bile ducts. *Rev Esp Enferm Dig.* 2019; 111(6):481-482.